

REVIEW ARTICLE

Nomenclature proposal for the sonographic description and reporting of soft tissue fillers

Leonie W. Schelke MD¹  | Daniel Cassuto MD² | Peter Velthuis MD, PhD¹ | Ximena Wortsman MD^{3,4,5}

¹Department of Dermatology, Academic Hospital, Rotterdam, The Netherlands

²Department of Plastic Surgery, Policlinico di Modena, University of Modena, Modena, Italy

³Department of Imaging, Institute for Diagnostic Imaging of the Skin and Soft Tissues, Santiago, Chile

⁴Department of Dermatology, Universidad de Chile, Santiago, Chile

⁵Department of Dermatology, Pontificia Universidad Católica de Chile, Santiago, Chile

Correspondence

Leonie W. Schelke, Department of Dermatology, Erasmus MC, Postbus 2040, 3000 CA, Rotterdam, The Netherlands.
Email: lschelke@outlook.com

Abstract

Background: There is a steady increase in publications about the use of ultrasound and filler treatments, written by physicians from different specialties. The terminology used to describe the ultrasound images of fillers is not uniform, making the different articles difficult to compare. Standardization of the descriptions based on their basic sonographic parameters is recommendable.

Aims: The purpose of this study is to propose a nomenclature for the sonographic description and reporting of cosmetic fillers.

Methods: An assessment of articles indexed for MEDLINE/PubMed and Embed electronic database was conducted; in total of 39 articles could be included.

Results: All articles were investigated for their sonographic descriptions of soft tissue fillers. Ten parameters used for describing and monitoring soft tissue fillers were distinguished.

Conclusion: The proposed sonographic descriptions for cosmetic fillers may contribute to a better standardization and understanding fillers ultrasound images in the reports or literature.

KEYWORDS

fillers, nomenclature, review, ultrasound

1 | INTRODUCTION

Modern era ultrasound devices are small, portable, practical, and increasingly affordable. Probes connectable to tablets or smartphones including software are available worldwide. The technique allows direct interaction with the patient. We feel that in the near future ultrasound will be an indispensable diagnostic tool in any dermatologists office.

The use of ultrasound for imaging soft tissue fillers, has been reported and recommended in a growing number of publications during the last decade.¹⁻⁷ The use of ultrasound is being promoted as it is a noninvasive imaging modality that provides a good definition for studying the skin and deeper layers in real time, including blood flow.⁸⁻¹²

Currently, ultrasound is considered the first-imaging technique for dealing with fillers and managing their potential complications,¹³⁻¹⁵ because it can detect and identify the most common types of cosmetic fillers,¹⁵⁻¹⁷ including their anatomical location, size, and depth.^{12,18} In cases where filler treatments have been performed previously, it can be helpful in patients without a clear history of fillers.^{13-15,19} In the clinical practice setting, ultrasound examination can support the diagnosis and treatment of early and late complications.^{16,17,19-22} In the case of hyaluronic acid fillers, hyaluronidase can be placed with ultrasound-guided injections exactly into the filler deposit.^{11,23}

The use of color Doppler, as in other indications of ultrasound, has been strongly suggested.^{9,15,21} This allows observation of the anatomical variants of the main facial arteries before treatment is performed.²¹

For research purposes, ultrasound examination provides valuable information on the behavior, longevity, and interaction of the filler within the tissues.²⁴⁻²⁹

All articles published describe the good visibility of different fillers and consider ultrasound as an asset for cosmetic medicine as it improves the safety of filler treatments. These papers have been published by physicians from different specialties and backgrounds; therefore, there is a wide range of terminology in the ultrasound description of the same type of filler. Interpreting these different descriptions may be confusing. For new applications, nomenclature should be unequivocal. Standardization of the descriptions based on basic sonographic parameters may lead to a better mutual understanding and interpretation. This paper examines ultrasound glossary for soft tissue fillers.

2 | METHODS

An assessment of articles indexed for MEDLINE/PubMed and Embase electronic database was conducted according to the PRISMA guidelines (Jan 2000–May 2018), which was restricted to papers published in English, using the relevant keywords: ultrasound [or] sonographic [and] dermal fillers, soft tissue filler, injectable filler, tissue augmentation, hyaluronic acid, collagen, poly-L-lactic acid, polycaprolactone, calcium hydroxyapatite, polyalkylimide, polyacrylamide, silicon oil, dimethylsiloxanes, polymethylmethacrylate, hydroxyethyl methacrylate lipofilling, complications, and adverse events.

As this topic is an innovative, developing area of cosmetic medicine, all studies excluding case reports were selected.

3 | RESULTS

In this assessment, a total of 39 articles (19 published in a journal for dermatology, 11 for plastic surgery, 9 for radiology) published between 2009 and 2018 could be included. Of these 39 articles, 12 described the ultrasound as a tool for research purposes, 10 to detect fillers and 17 articles mention the follow-up and treatment of complications.

All of these articles were investigated for their sonographic descriptions of soft tissue fillers and described in Table 1.

Furthermore, the main parameters used for describing and monitoring soft tissue fillers were grouped. In total, ten parameters were distinguished. Among these, echogenicity was the most common parameter reported. Echogenicity is the characteristic reflection of sound waves generated by a tissue expressed in the gray scale. Four scales are being used as follows:

- Anechoic when there are no echoes and the structure appears black on screen.
- Hypoechoic when there are low reflectiveness and density of echoes; a structure will appear as varying shades of gray.

- Hyperechoic when there is highly reflectiveness and an echo rich structure when compared to neighboring structures; it appears as varying tones of white.
- Isoechoic when the structure appears with similar echogenicity to a neighboring structure.

The other nine parameters extracted from the articles were texture, border, shape, quantity, diameter, artifacts, internal characteristics, anatomical location, and evolution. However, the descriptions of these parameters differed widely in the reports.

For example, the sonographic glossary will use the term “homogenous” or “heterogeneous” to describe the texture of a structure. However, some articles mention “regular” instead of homogeneous. Furthermore, sharp regular borders or distinct walls were re-defined as “well-defined”. Inner spots or an irregular inner pattern were categorized as “internal echoes”.

All articles mention the anatomical location of the soft tissue filler identified with ultrasound and most of them describe the filler changes over time. The ten parameters and their subtypes were extracted from literature and shown in Table 2.

3.1 | Sonographic parameters for identifying and reporting fillers

As mentioned above, the following sonographic parameters were commonly reported in the articles and may be relevant for identifying, monitoring, and reporting fillers:

3.1.1 | Echogenicity

Soft tissue fillers present distinctive sonographic patterns of echogenicity.¹⁵ For example, water-based (hydrophilic) fillers will give a different ultrasound image compared with hydrophobic fillers. All hydrophilic fillers are able to bind water and are usually injected as a gel; therefore, the sound waves will easily pass through and they appear as anechoic (black) on screen. Most hydrophobic fillers are made from synthetic materials and do not degrade in tissue. Examples of these fillers are silicon oil and polymethylmethacrylate (PMMA).²⁹ These type of fillers contain microspheres that provoke variable degrees of intense reflection of the sound waves; therefore, they appear as hyperechoic (white) on the screen.³⁰ Some fillers may change in echogenicity over time as their water-soluble gel vehicle may be reabsorbed.

3.1.2 | Texture

The texture within the deposits may be homogeneous or heterogeneous.

Homogeneous: the filler deposit is uniform in echogenicity. Heterogeneous: the filler deposit is not uniform in echogenicity. For example, silicone oil tends to appear as homogeneously hyperechoic.^{3,4,30-32} In contrast, polycaprolactone shows a mixed echogenicity with a hypoechoic matrix that contains hyperechoic spots.³¹

TABLE 1 Ultrasound descriptions of cosmetic fillers reported in the medical literature

Hyaluronic acid
Scattered anechoic round structures pseudocysts, ² fairly distinct hypoechoic (black) lesion with some hyperechoic (linear) reflections, ³ anechoic or hypoechoic round or oval pseudocystic structures, ⁹ well-defined regular hypoechoic mass without any signs of internal echoes, ^{11,23} oblong, homogeneous papule, with an isoechoic aspect, ³⁹ mixture of iso- and hypoechoic pools, ³⁹ dark nonechogenic zone, ¹⁵ oval-shaped anechoic pseudocystic structures, ¹⁷ cross linked: heterogeneous echogeneous appearance of papulae, ¹⁹ monophasic: homogenous papule that was as dense as the surrounding tissue, ¹⁹ small anechoic pseudocystic structures, ²² hyaluronic acid depots, ²⁷ anechoic pearls, ²⁸ anechoic bubble with diffuse margins, ²⁸ largely anechoic with internal echoes called “the sparkly lake sign”, ²⁹ a well-defined regular hypoechoic mass or band, ³⁰ well-defined, hypoechoic subcutaneous lesions without any signs of internal echoes, ³² hypoechoic pseudocyst ³³ anechoic (black) and hypoechoic deposit ³⁴
Calcium hydroxyapatite
Hyperechoic tissue (shadowing), ³ hyperechoic deposits with variable degrees of acoustic shadowing due to calcium, ^{2,8} hyperechoic deposits with posterior acoustic shadowing artifact, ^{7,22} hypoechoic but with denser areas inside ²⁴
Polycaprolactone
Bright hyperechoic spots with a mini-comet-tail artifact within a hypoechoic matrix ¹⁸
Polyalkylimide (PAIG)
Anechoic with water-like aspect in recent implants and corpusculated in older ones, ¹⁰ hyperechoic mass with a distinct edge from surrounding tissues, with small echoes inside, ¹¹ anechoic oval pseudo cystic structures, ²⁰ hyperechoic mass with inner spots, ²¹ oval-shaped anechoic pseudocystic structures, ^{22,26} hyperechoic pattern surrounded by a wall ²⁴
Polyacrylamide (PAAG)
Anechoic to hypoechoic lesions with distinct echogenic walls, ³ hyperechoic mass with inner spots, ^{11,21} anechoic round or oval-shaped pseudocystic structures, ¹⁷ hyperechoic mass and containing a spot of linear diffusion of the material ²¹ increased hypodermal echogenicity in the vicinity of the deposits, ²² hyperechoic pattern surrounded by a wall ²⁴
Silicon oil
Hyperechoic deposits (snow storm) with high degree of sound scattering, ² shadowing due to tight fibrotic tissue, ³ snowstorm pattern, ^{11,24} hyperechoic deposits with a posterior reverberance that produces a “snowstorm” artifact ⁷ hyperechoic, with a posterior reverberation artifact, ¹⁷ strong acoustic shadow ²¹
Pure silicon
Anechoic ² Anechoic round or oval-shaped pseudocystic structures, ¹⁷ oval anechoic lacunar areas ²²
Polymethylmethacrylate (PMMA)
Multiple bright hyperechoic dots producing mini-comet tail artifact, ^{2,17} hyperechoic dots producing mini-comet tail shaped artifact, ²² shadowing due to tight fibrotic tissue, ³ large and old deposits may show reverberance) after 6 mo: posterior acoustic shadowing artifact ¹⁷

(Continues)

TABLE 1 (Continued)

Hydroxyethyl methacrylate (HEMA)
Diffusely hyperechoic appearance ²⁰
Lipofilling
A well-defined, compact, finely textured area and are isoechoic to slightly hyperechoic, ³ lobulated hypoechoic deposits with some hyperechoic linear septa, ¹⁷ area of hyperechogenicity with regular margins ³¹

3.1.3 | Border

Hydrophilic fillers have a well-defined border whereas hydrophobic fillers tend to be ill-defined.^{30,31} Resorbable polymeric fillers such as polycaprolactone may change in contour over time, as the hydrophilic gel carrier is being reabsorbed, the polyesters alone may remain visible as bright hyperechoic spots.³²

3.1.4 | Shape

Hydrophilic fillers tend to have an oval or round shape. Some synthetic fillers that come in a gel such as polyacrylamide tend to maintain their oval or rounded shape, echogenicity, and size during extended periods of time, usually years.^{2,31,33} In contrast, pure hyaluronic acid (noncross-linked) deposits tend to modify their shape over months.^{34,35} Other filler may have a different appearance as band- or mass-like.

3.1.5 | Diameter

The most widely used hydrophilic filler is hyaluronic acid. This filler are meant for different treatment applications and duration and are injected in different depot sizes.³⁶ The diameter can be measured during ultrasound examination, and changes in size may be followed up.^{26,31}

3.1.6 | Quantity

Depending on the technique, one large dark bolus injected for volume or a line of multiple deposits may be visible in the path of the injection.^{2,28}

3.1.7 | Internal characteristics

Some hydrophilic fillers such as hyaluronic acid present variations in their echogenicity over time due to the loss of the gel vehicle that contains the deposits and may become more hypoechoic and/or may show inner echoes.^{32,37,38} Examples of this situation are the long-lasting or cross-linking types of hyaluronic acid and polymeric fillers with gel vehicles.³¹

3.1.8 | Artifacts

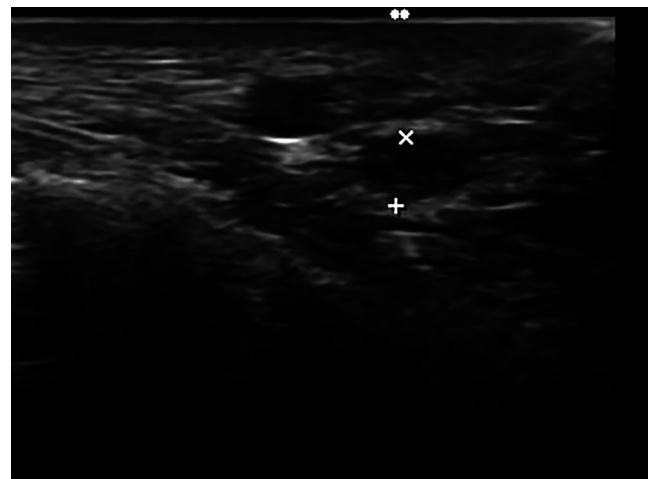
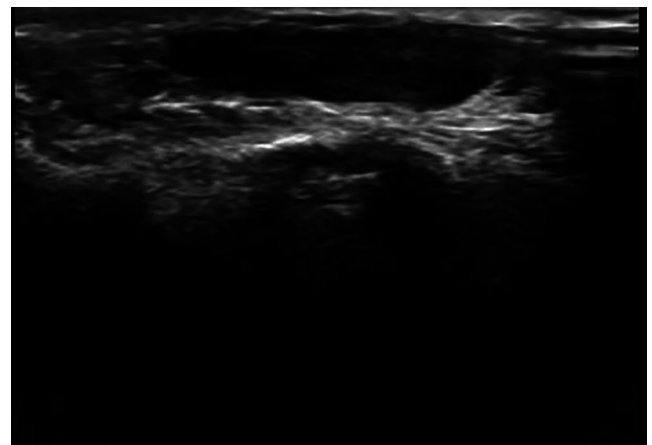
Most hydrophobic fillers are made from synthetic materials and do not degrade in tissue. On sonography, they show different patterns of posterior acoustic artifacts which can allow their

TABLE 2 Description of parameters of sonographic fillers

Parameter	Description	Description	Description	Description
Echogenicity	Anechoic	Hypoechoic	Isoechoic	Hyperechoic
Texture	Homogeneous: the filler deposit is uniform in echogenicity	Heterogeneous: The filler deposit is not uniform in echogenicity		
Border	Well-defined	Ill-defined		
Shape	Oval	Round	Band-like	Mass-like
Quantity: when the deposits can be delimited or separated into units	Single	Multiple		
Diameter: measurements in mm or cm	Small deposits: a representative sample of the size of the deposits can be taken	Wide or diffuse dispersion of the deposits		
Artifacts	Posterior Reverberance "snow storm"	Mini-comet tail	Posterior acoustic shadowing	
Internal characteristics	Internal echoes	Septa	Hyperechoic calcifications	
Anatomical location				
Evolution	Shape	Size	Echogenicity	Content

TABLE 3 Sonographic descriptions for cosmetic fillers

Hyaluronic acid	Well-defined oval- or round-shaped anechoic homogeneous deposits without any signs of internal echoes.
Calcium hydroxyapatite	Well-defined band-like hyperechoic deposit with posterior acoustic shadowing artifact
Polycaprolactone	Ill-defined hypoechoic matrix that contain bright hyperechoic spots with a mini-comet tail artifact
Polyalkylimide	Hypoechoic mass, hyperechoic pseudocapsule, containing a spot of linear, sometimes an irregular pattern of hyperechoic material within the mass
Polyacrylamide	Well-defined, oval-shaped anechoic homogeneous deposits that produce posterior acoustic
Silicon oil	Ill-defined, hyperechoic mass-like deposits that produce diffuse posterior reverberation ("snow storm pattern").
Polymethylmethacrylate	Ill-defined, hyperechoic mass-like deposits that produce mini-comet tail artifacts
Hydroxyethylmethacrylate	Ill-defined, hyperechoic mass-like deposits
Lipofilling	Hypoechoic, heterogeneous well-defined oval-shaped mass-like deposit (marker 2) with some hyperechoic linear septa

**FIGURE 1** hyaluronic acid; two anechoic, homogeneous, well-defined oval-shaped deposits, one of them between markers**FIGURE 2** Polyalkylimide: an anechoic, homogeneous, well-defined, oval-shaped single oval deposit (without internal echoes)

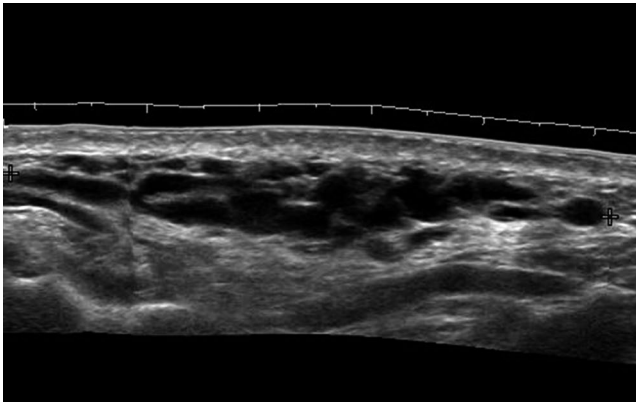


FIGURE 3 Polyacrylamide: anechoic, homogeneous, and well-defined, multiple deposits with a slight posterior reinforcement artifact

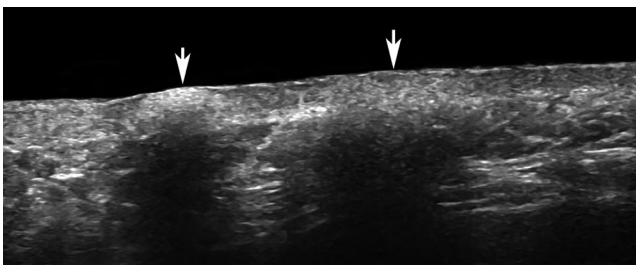


FIGURE 4 Calcium hydroxyapatite: two hyperechoic, well-defined band-like deposits (arrows) with posterior acoustic shadowing artifact




FIGURE 5 Silicon oil: hyperechoic, heterogeneous, ill-defined, mass-like deposits that produce diffuse posterior reverberation artifact ("snow storm pattern")

identification.¹¹ Silicone oil produces a high reflection and a diffuse posterior reverberance artifact called "snow storm." Other fillers such as polymethylmethacrylate generate a strong and tiny posterior reverberance of the sound waves which is called mini-comet tail artifact. Additionally, these fillers may generate a dense fibrotic reaction around the particles of the material

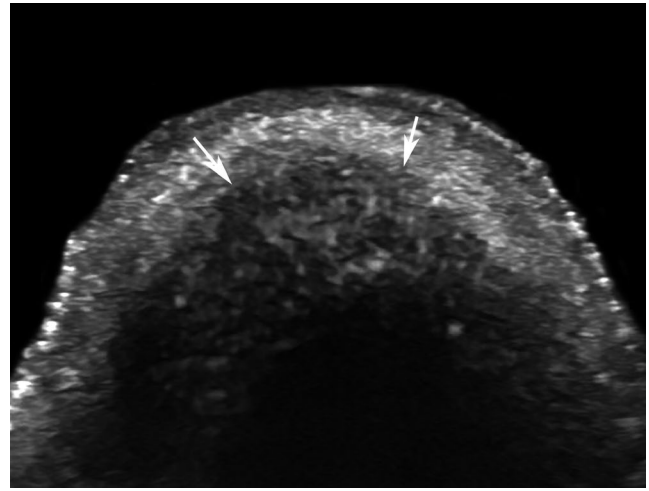


FIGURE 6 Polycaprolactone: hypoechoic, heterogeneous and ill-defined matrix (arrows) that contains multiple bright hyperechoic spots that present a posterior mini-comet tail artifact

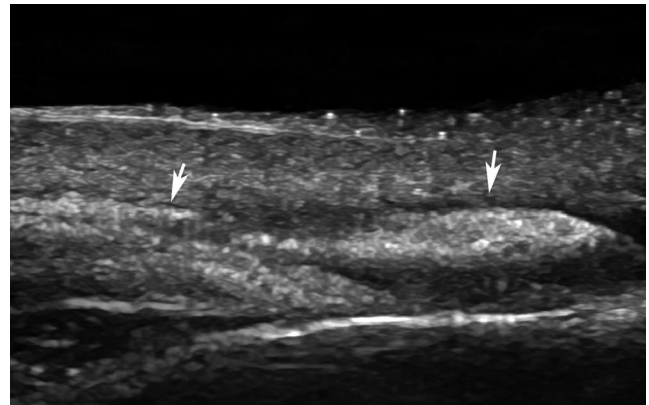


FIGURE 7 Polymethylmethacrylate (PMMA): hyperechoic, heterogeneous, ill-defined, mass-like deposits (arrows) that produce mini-comet tail artifacts

that can produce areas with posterior acoustic shadowing artifact.^{3,25}

3.1.9 | Anatomical location

Another important point to bear in mind is that fillers used for increasing the volume will be injected on a deeper plane, usually close to the bony margin. In contrast, fillers for treating wrinkles are injected more superficially,^{31,32}

3.1.10 | Evolution

The intrinsic characteristics of each filler will generate variations in their ultrasound appearance. For example, hyaluronic acid deposits tend to modify their shape, decrease in size and become more hypoechoic over time.^{37,38}

In Table 3 and the Figures 1-8 underneath, these parameters are applied to the most commonly fillers used.

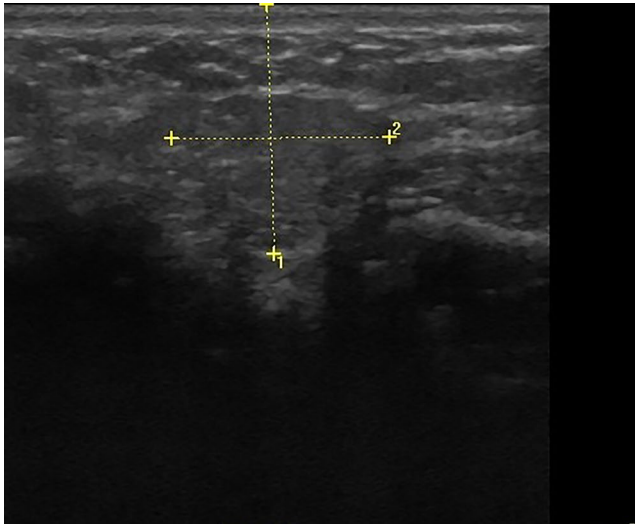


FIGURE 8 Lipofilling: hypochoic, heterogeneous well-defined oval-shaped mass-like deposit (marker 2) with some hyperechoic linear septa that disrupt the architecture of the neighboring fatty tissue of the subcutis. Marker 1 is showing the distance from the epidermal surface to the bottom of the fatty graft

4 | CONCLUSION

In this article, we examined the terminology and parameters used to describe soft tissue fillers. One of the current shortcomings is that data and patient numbers described in the existing publications are limited. More extensive data and prospective series are necessary to evaluate and if necessary adjust the proposed parameters in the future.

Although sometimes lacking sonographic glossary, most articles focus on the same parameters.

A proposal considering ten sonographic parameters for identifying, monitoring, and reporting these deposits on ultrasound is herewith provided. We notice that incorporating these parameters improves an accurate and uniform terminology. It may serve as a guideline for dermatologists using ultrasonography in their offices. Furthermore, it may contribute to standardize future literature and reports and facilitate the comparison of research.

CONFLICTS OF INTEREST

None declared.

ORCID

Leonie W. Schelke  <https://orcid.org/0000-0002-5512-1956>

REFERENCES

- Cassuto D, Sundaram H. A problem-oriented approach to nodular complications from hyaluronic acid and calcium hydroxylapatite fillers: classification and recommendations for treatment. *Plast Reconstr Surg.* 2013;132(4 suppl 2):485-585.
- Cassuto D. Management of complications caused by permanent fillers in the face: a treatment algorithm. *Plast. Reconstr. Surg.* 2016;138:215e.
- Wortsman X, Wortsman J, Orlandi C, Cardenas G, Sazunic I, Jemec GB. Ultrasound detection and identification of cosmetic fillers in the skin. *J Eur Acad Dermatol Venereol.* 2012;26(3):292-301.
- Schelke LW, Van Den Elzen HJ, Erkamp PP, Neumann HA. Use of ultrasound to provide overall information on facial fillers and surrounding tissue. *Dermatol Surg.* 2010;36(suppl 3):1843-1851.
- Young SR, Bolto PA, Downie J. Use of high frequency ultrasound in the assessment of injectable dermal fillers. *Skin Res Technol.* 2008;14:320-323.
- Scotto di Santolo M, Sagnelli M, Tortora G, et al. The utility of the high-resolution ultrasound technique in the evaluation of autologous adipose tissue lipofilling, used for the correction of post-surgical, post-traumatic and post-burn scars. *Radiol Med.* 2016;121(6):521-527.
- Fiaschetti V, Pistolesse CA, Fornari M, et al. Magnetic resonance imaging and ultrasound evaluation after breast autologous fat grafting combined with platelet-rich plasma. *Plast Reconstr Surg.* 2013;132(4):498e-509e.
- Wortsman X, Alfageme F, Roustan G, et al. Guidelines for performing dermatologic ultrasound examinations by the DERMUS group. *J Ultrasound Med.* 2016;35(3):577-580.
- Rallan D, Harland CC. Ultrasound in dermatology – basic principles and applications. *Clin Exp Dermatol.* 2003;28:632-638.
- Barcaui EO, Carvalho ACP, Lopes FPPL, Piñeiro-Maceira J, Barcaui CB. High frequency ultrasound with color doppler in dermatology. *An Bras Dermatol.* 2016;91(3):262-273.
- Iwayama T, Hashikawa K, Osaki T, Yamashiro K, Horita N, Fukumoto T. Ultrasonography-guided cannula method for hyaluronic acid filler injection with evaluation using laser speckle flowgraphy. *Plast Reconstr Surg Glob Open.* 2018;6(4):e1776.
- Kwon HJ, Kim BJ, Ko EJ, Choi SY. The utility of color Doppler ultrasound to explore vascular complications after filler injection. *Dermatol Surg.* 2017;12(43):1508-1510.
- Skrzypek E, Górnicka B, Skrzypek DM, Krzysztof MR. Granuloma as a complication of polycaprolactone-based dermal filler injection: ultrasound and histopathology studies. *J Cosmet Laser Ther.* 2018;14:1-4.
- Seok J, Kim JM, Kwon TR, Kim JH, Li K, Kim BJ. Ultrasonography-guided curettage of poly-DL-lactic acid filler granulomas. *J Am Acad Dermatol.* 2018;78(1):e5-e6.
- Pérez-Pérez L, García-Gavín J, Wortsman X, Santos-Briz Á. Delayed adverse subcutaneous reaction to a new family of hyaluronic acid dermal fillers with clinical, ultrasound and histologic correlation. *Dermatol Surg.* 2017;43(4):605-608.
- Wortsman X. Sonography of dermatologic emergencies. *J Ultrasound Med.* 2017;36(9):1905-1914.
- Indrizzi E, Moricca LM, Pellacchia V, Leonardi A, Buonaccorsi S, Fini G. Biomaterial implantation in facial esthetic diseases: ultrasonography monitor follow-up: follow up after bio alcamid. *J Craniofac Surg.* 2008;19(4):1098-1103.
- Schelke LW, Decates TS, Van der Lugt C, Pelzer L, de Mey G, Velthuis PJ. Intralesional laser treatment for dermal fillers complications. *Plast. Reconstr. Surg.* 2018;141(6):1361-1369.
- Grippaudo FR, Mattei M. The utility of high-frequency ultrasound in dermal filler evaluation. *Ann Plast Surg.* 2011;67(5):469-473.
- Grippaudo FR, Mattei M. High frequency sonography of temporary and permanent dermal fillers. *Skin Res Technol.* 2010;16:265-269.
- Wortsman X, Wortsman J. Polyacrylamide fillers on skin ultrasound. *J Eur Acad Dermatol Venereol.* 2012;26(5):660-661.

22. Faundez E, Vega N, Vera E, Vega P, Sepulveda D, Wortsman X. Clinical and color Doppler ultrasound evaluation of polyacrylamide injection in HIV patients with severe facial lipoatrophy secondary to antiretroviral therapy. *Skin Res Technol.* 2017;23:243-248.
23. Schelke LW, Decates TS, Velthuis PJ. Ultrasound to improve the safety of hyaluronic acid filler treatments. *J Cosmet Dermatol.* 2018;17(6):1019-1024.
24. Micheels P, Besse S, Sarazin D, Vincent AG, Portnova N, Diana MS. Quantifying depth of injection of hyaluronic acid in the dermis: data from clinical, laboratory, and ultrasound settings. *J Drugs Dermatol.* 2016;15(4):483-490.
25. Micheels P, Besse S, Sarazin D. Two crosslinking technologies for superficial reticular dermis injection: a comparative ultrasound and histologic study. *Clin Aesthet Dermatol.* 2017;10(1):29-36.
26. Tedeschi A, Lacarrubba F, Micali G. Mesotherapy with an intradermal hyaluronic acid formulation for skin rejuvenation: an intrapatient, placebo-controlled, long-term trial using high-frequency ultrasound. *Aesth Plast Surg.* 2015;39:129-133.
27. Turlier V, Rouquier A, Black D, et al. Assessment of the clinical efficacy of a hyaluronic acid-based deep wrinkle filler using new instrumental methods. *J Cosmet Laser Ther.* 2010;12(4):195-202.
28. Micheels P, Besse S, Flynn TC, Sarazin D, Elbaz J. Superficial dermal injection of hyaluronic acid soft tissue fillers: comparative ultrasound study. *Dermatol Surg.* 2012;38:1162-1169.
29. Vent J, Lefarth F, Massing T, Angerstein W. Do you know where your fillers go? An ultrastructural investigation of the lips. *Clin Cosmet Investig Dermatol.* 2014;20(7):191-199.
30. Grippaudo FR, Di Girolamo M, Mattei M, Pucci E, Grippaudo C. Diagnosis and management of dermal filler complications in the perioral region. *J Cosmet Laser Ther.* 2014;16(5):246-252.
31. Wortsman X, Jemec G. *Dermatologic Ultrasound with Clinical and Histologic Correlations.* New York: Springer Science+Business Media; 2013.
32. Wortsman X. Identification and complications of cosmetic fillers: sonography first. *J Ultrasound Med.* 2015;34(7):1163-1172.
33. Wortsman X, Quezada N. Ultrasound morphology of polycaprolactone filler. *J Ultrasound Med.* 2017;13:2611-2615.
34. Scotto di Santolo M, Massimo C, Tortora G, et al. Clinical value of high-resolution (5–17 MHz) echo-color doppler (ECD) for identifying filling materials and assessment of damage or complications in aesthetic medicine/surgery. *Radiol Med.* 2019;124:568-574.
35. Giovagnorio F, Drudi FM, Valentini C, Paonessa A. Ultrasound in follow up of soft tissue augmentation of the face with synthetic materials; a pilot study. *Acta Radiol.* 2004;45:746.
36. De Pasquale A, Russa G, Pulvirenti M, Di Rosa L. Hyaluronic acid filler injections for tear-trough deformity: injection technique and high-frequency ultrasound follow-up evaluation. *Aesthetic Plast Surg.* 2013;37:587-591.
37. Goh AS, Kohn JC, Rootman DB, Lin JL, Goldberg RA. Hyaluronic acid gel distribution pattern in periocular area with high-resolution ultrasound imaging. *Aesthetic Surg J.* 2014;34:510-515.
38. Kohn JC, Goh AS, Lin JL, Goldberg RA. Dynamic high resolution ultrasound in vivo imaging of hyaluronic acid filler injection. *Dermatol Surg.* 2013;39:1630-1636.
39. Mlosek RK, Skrzypek E, Skrzypek DM, Malinowska S. High-frequency ultrasound-based differentiation between nodular dermal filler deposits and foreign body granulomas. *Skin Res Technol.* 2018;24(3):417-422.

How to cite this article: Schelke LW, Cassuto D, Velthuis P, Wortsman X. Nomenclature proposal for the sonographic description and reporting of soft tissue fillers. *J Cosmet Dermatol.* 2019;00:1-7. <https://doi.org/10.1111/jocd.13127>